Profound Cardiac Decompensation during Labor and Delivery

NNEPQIN Conference

6/8/23

Financial Disclosures

- No relevant disclosures

Goals

1. Use a case report to help rapidly identify acute peripartum cardiopulmonary collapse
2. Develop a differential diagnosis for these symptoms
3. Review the standard of care for resuscitative measures during this rare event
4. Discuss possible supplemental management measures emerging in the literature

Case: Obstetric and Labor History

- Multiparous woman presented for external cephalic version
  - Two prior vaginal deliveries
  - Pregnancy complicated by moderate polyhydramnios and unstable lie
  - Successful ECV day of admission
- Underwent IOL for unstable lie
- Scanned during IOL, and transverse again
- Elected to proceed with primary low transverse cesarean section

Case: Surgery

- Uncomplicated until delivery of infant
- Seizure activity noted by anesthesia
- Atony noted during closure of hysterotomy

Methergine → Hemabate → Rectal misoprostol

Case: Code and Differential Diagnosis

- Loss of pulse during hysterotomy closure
- Code called, chest compressions commence prior to closure of fascia
- Differential diagnosis
  - Pulmonary embolism/air embolism
  - High spinal
  - Eclampsia
  - Anaphylaxis
  - Amniotic fluid embolism

Case: DIC and Postop Management

- Presumed AFE, recommended A-OK protocol (Atropine, ondansetron, ketorolac)
- Standard ACLS continued
- Shocked x1→ ROSC obtained
- Called for MTP for impending DIC
- Bakri placed

Amniotic Fluid Embolism

- Incidence: 1.9-6.1 cases per 100,000 deliveries—as few as 40/year in US
  - Risk factors: Cesarean, induction of labor, operative vaginal delivery, multiparity, AMA, preeclampsia, placenta previa, cervical laceration, uterine rupture, or multiple gestation
  - Fatality rate
    - Wide range in the literature, ~10-90% (46% for AFE, cardiac arrest, and DIC)
    - Rate of maternal deaths due to AFE in USA and Europe found to be 13.7%

Diagnostic Criteria

- Diagnostic Criteria (all 4 present):
  - 1. Sudden cardiac arrest, or hypotension and respiratory compromise
  - 2. overt DIC after these symptoms
  - 3. Onset during labor/within 30 minutes
  - 4. Absence of fever

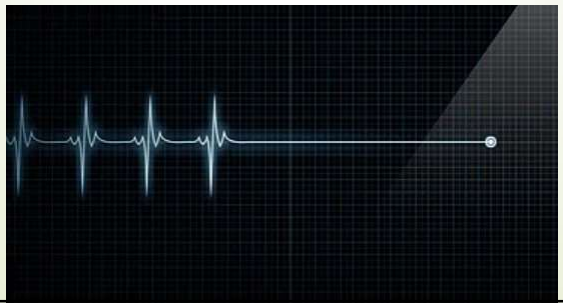

Pathogenesis

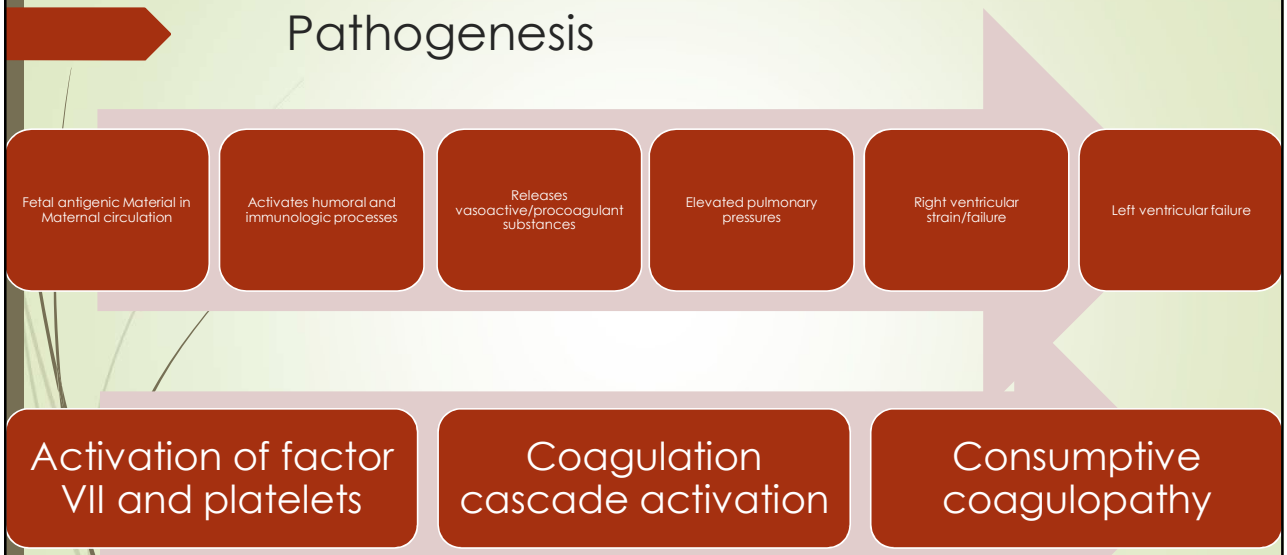

Standard Treatment

- Treatment per sMFM
  - Standard ACLS measures
  - Immediate delivery if >23 weeks
  - Ventilate, oxygenate, and use vasopressors and inotropes for initial management
    - Avoid excessive fluids
  - Massive transfusion protocol for coagulopathy
  - Supportive care

Society for Maternal·Fetal Medicine

A-OK for AFE

- Technically experimental
  - Two case reports in the literature with symptoms improving after A-OK as adjunct
  - Multiple unpublished posters and case series
- Atropine 1 mg IV → Vagal Response
- Ondansetron 8 mg IV → Serotonin
- Ketorolac 30 mg IV → Thromboxane A2

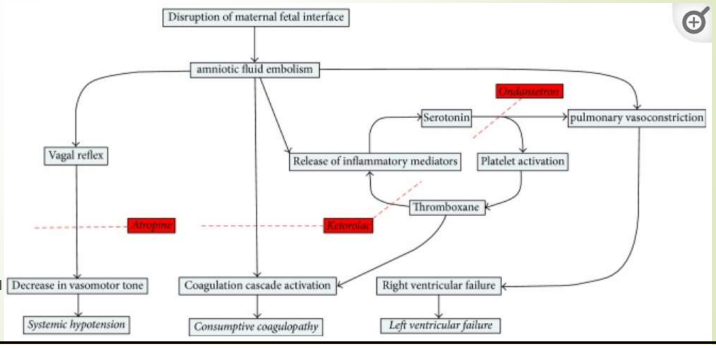

Rezai S, Hughes AC, Larsen TB, Fuller PN, Henderson CE. Atypical Amniotic Fluid Embolism Managed with a Novel Therapeutic Regimen. Case Rep Obstet Gynecol. 2017;2017:8458375

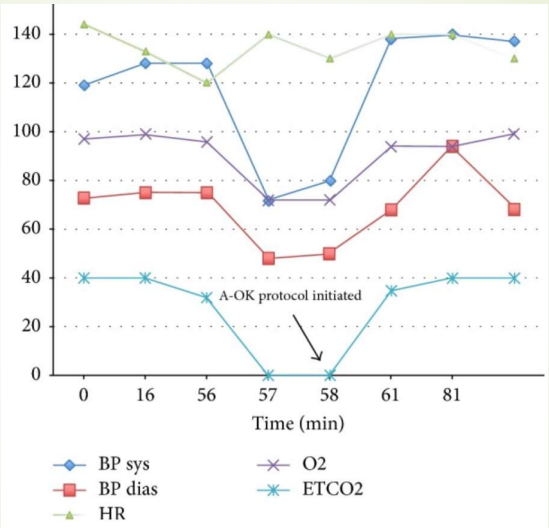

Rezai S, Hughes AC, Larsen TB, Fuller PN, Henderson CE. Atypical Amniotic Fluid Embolism Managed with a Novel Therapeutic Regimen. Case Rep Obstet Gynecol. 2017;2017:8458375

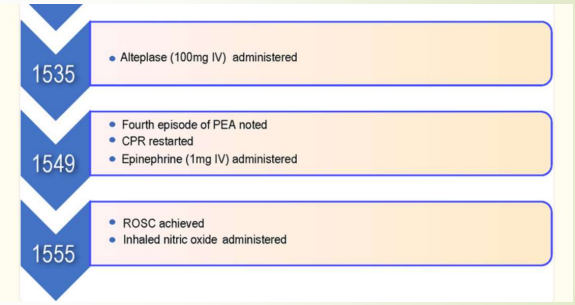

Long M, Martin J, Biggio J. Atropine, Ondansetron, and Ketorolac: Supplemental Management of Amniotic Fluid Embolism. Ochsner J. 2022 Fall;22(3):253-257.

Case Report: AOK Given

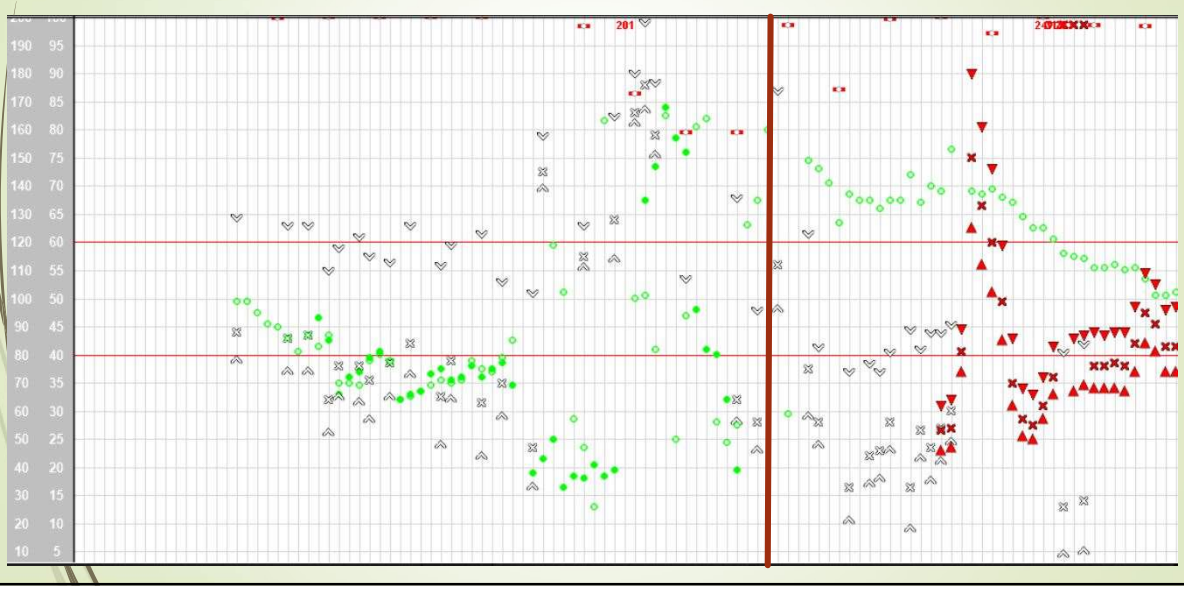

Take Aways

- Amniotic fluid embolism is a rare but dangerous clinical diagnosis that should be considered in any profound peripartum cardiopulmonary collapse
- Rapid diagnosis and treatment with ACLS, MTP, and coordination of care is imperative for a good outcome
- New supplemental treatment options are developing
- More research and case reports are needed to improve data on new treatment options

List of References

- Clark, SL, *et al*. Proposed diagnostic criteria for the case definition of amniotic fluid embolism in research studies. Am J Obstet Gynecol 2016;217:408-412.
- Long M, Martin J, Biggio J. Atropine, Ondansetron, and Ketorolac: Supplemental Management of Amniotic Fluid Embolism. Ochsner J. 2022 Fall;22(3):253-257.
- Rezai S, Hughes AC, Larsen TB, Fuller PN, Henderson CE. Atypical Amniotic Fluid Embolism Managed with a Novel Therapeutic Regimen. Case Rep Obstet Gynecol. 2017;2017:8458375
- Society for Maternal-Fetal Medicine (SMFM) with the assistance of Pacheco LD, Saade G, *et al*. Amniotic fluid embolism: Diagnosis and management. Am J Obstet Gynecol 2016;215:B16-24.

Questions